

A swallowed sewing needle migrating to the liver

Serhat Avcu¹, Özkan Ünal¹, Özkan Özen¹, Aydın Bora¹, Ahmet Cumhuri Dülger²

Departments of Radiology¹ and Gastroenterology²
Yüzüncü Yil University School of Medicine, Van, Turkey.

Citation: Avcu S, Ünal Ö, Özen Ö, Bora A, Dülger AC. A swallowed sewing needle migrating to the liver. **North Am J Med Sci** 2009; 1: 193-195.

Availability: www.najms.org

ISSN: 1947 – 2714

Abstract

Context: Swallowing foreign bodies is a common problem in children. Although most objects pass through the gastrointestinal tract with no untoward effect; long, sharp-pointed, or slender objects can perforate the gut. Migration of a swallowed object to the liver is extremely rare and very few cases have been reported in the literature up to now. The aim of this study is to draw attention to this subject once again by contributing a case report of a child with hepatic migration of a swallowed sewing needle. **Case Report:** A 16-year-old girl presented to the emergency room of pediatrics department in our hospital with complaints of abdominal pain, nausea and vomiting. Physical examination revealed tenderness on the right upper quadrant of the abdomen. Laboratory examination revealed increased hepatic enzymes as well as increased white blood cell count. Abdominal ultrasonography and computed tomography examinations revealed foreign body in the liver accompanied by surrounding abscess formation. The foreign body (sewing needle) was removed surgically after two operations. **Conclusion:** The children may not be able to remember the swallowing of the foreign body or they may try to hide such a condition. The radiological diagnosis in such cases which can be achieved by X-rays, ultrasonography or computed tomography is of critical importance, as well as getting detailed patient history for foreign body swallowing.

Keywords: foreign body swallowing, migration, hepatic, liver.

Correspondence to: Serhat Avcu, MD., Assistant Professor. YYU Radyoloji A.D., 65200 Van, Turkey. Tel.: +90 432 2168496. Email: serhatavcu@hotmail.com

Introduction

Foreign body swallowing is not an uncommon problem in children. The majorities of foreign bodies pass harmlessly through the gastrointestinal tract and is eliminated in the stool [1, 2]. However, swallowed sharp foreign bodies can rarely perforate the gut [3]. Perforation of the intestine by foreign bodies with migration to the liver is extremely rare, and very few cases have been reported in the literature [1, 3, 4]. We report a case of 16-year-old girl who swallowed a sewing needle accidentally, which silently perforated the stomach, and migrated to the right lobe of the liver, with demonstrative radiological findings.

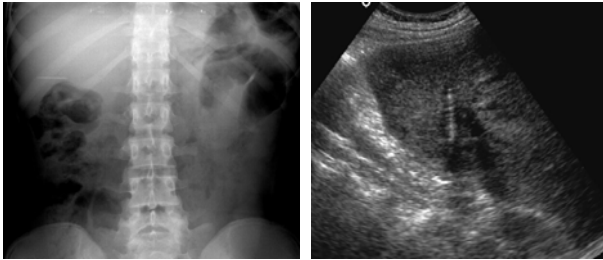
Case Report

A 16-year-old girl presented to the emergency room of pediatrics department in our hospital with complaints of

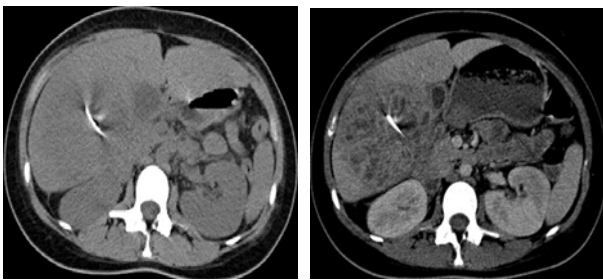
abdominal pain, nausea and vomiting. Physical examination revealed tenderness on the right upper quadrant of the abdomen. Blood analysis showed increased white blood count (15, 91/ μ l) with left shift, an erythrocyte sedimentation rate of 78 mm/h, and C-reactive protein (CRP) 279 mg/l. The other laboratory examinations revealed increased levels of Aspartate transaminase (AST): 57 U/L, Alanine aminotransferase (ALT): 104.91 U/L, Lactate dehydrogenase (LDH): 599 U/L, and Alkaline phosphatase (ALP): 575 U/L.

On abdominal X-ray, a metallic linear radio opaque image compatible with a foreign body was seen on right hepatic lobe localization (Fig. 1). Abdominal ultrasonography (US) examination revealed a 3cm long linear echogeneity in segment 5 surrounded by an irregularly contoured heterogeneous hyper echoic area of 10x7cm in size (Fig. 2), and made us think about migration of a swallowed

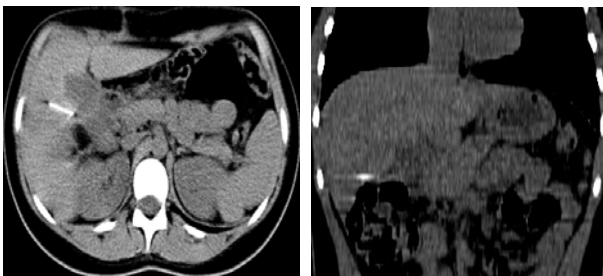
foreign body into the liver accompanied by an abscess formation. The patient was unaware of having swallowed any foreign body, but when we insisted on any possibility of such a condition, she remembered that she could have swallowed a sewing needle approximately a month ago while drinking water. She told that she saw a number of sewing needles in the water glass which she noticed after drinking some water. On further examination with abdominal computed tomography (CT), the metallic foreign body and surrounding inflammation were better demonstrated (Figs. 3, 4).



Figs. 1 & 2 On X-ray and US, the metallic foreign body is seen in the right hepatic lobe.



Figs. 3 & 4 On CT, the metallic foreign body and surrounding inflammatory reaction is demonstrated.



Figs. 5 & 6 Control CT examination 2.5 months after the first operation showed the inferomedial migration of the metallic foreign body near to the gallbladder.

The patient underwent surgical operation for the excision of the foreign body, but it could not be reached, and it was failed to get the foreign body due to patient's condition change during the operation. The patient went home with antibiotherapy for the surrounding inflammation. Two and a half months later the patient presented again with abdominal pain, and control CT examination demonstrated the migration of the foreign body inferomedially near to the gallbladder (Figs. 5, 6). The surrounding inflammatory changes were disappeared. On reoperation with open

abdominal surgery, the sewing needle was found easily due to its migration nearby the gallbladder, and it was removed from the liver. The patient recovered successfully after the operation.

Discussion

The majority of swallowed foreign bodies pass through the gastrointestinal tract uneventfully. Hepatic foreign bodies are rare, and may enter the liver by migration from the gastrointestinal (GI) tract, direct penetration through the abdominal wall, or via the bloodstream [2].

Perforation of the GI tract by swallowed foreign bodies is very rare, occurring in less than 1% of patients and it has been observed most commonly at the ileocecal and rectosigmoid region [3]. In this situation, peritonitis or a localized abscess were most common presentations [2]. The most common swallowed foreign bodies causing perforation are fish bones, chicken bones and needles [1, 5]. Although foreign bodies can migrate to any abdominal organ, perforation of the stomach and migration to the liver is extremely rare and only one pediatric hepatic sewing needle case that had passed from stomach has been reported in the literature [1].

Foreign bodies can reach to the liver by one of three routes: direct penetration through the abdominal wall, migration from the gastrointestinal tract, or via the bloodstream [2, 5]. Migration of the needles can usually be asymptomatic or can be a cause of acute abdomen [1–3]. In case that foreign body was not found in the gastrointestinal system and also a perforation site was found anywhere, the surgeon must carefully evaluate the liver. For the foreign bodies in the stomach and duodenum, the general management is usually conservative. In situations such as the present case that if there is a history of sharply-pointed foreign body swallowing and failure of progression and also signs of an acute abdomen there can be indications for surgery [1, 3]. Traditional surgical treatment requires laparotomy for foreign body removal [1, 5] but laparoscopic approach for intestinal foreign bodies is also reported [6].

In conclusion, the children may not be able to remember the swallowing of the foreign body or they may try to hide such a condition. The radiological diagnosis in such cases which can be achieved by X-rays, US or CT is of critical importance, as well as getting detailed patient history for foreign body swallowing.

References

1. Abel RM, Fischer JE, Hendren WH. Penetration of the alimentary tract by a foreign body with migration to the liver. *Arch Surg.* 1971; 102(3):227–228.
2. Crankson SJ. Hepatic foreign body in a child. *Pediatr Surg Int.* 1997; 12(5-6):426–427.
3. Chintamani, Singhal V, Lubhana P, Durkhere R, Bhandari S. Liver abscess secondary to a broken needle migration: a case report. *BMC Surg.* 2003; 3:8.

4. Azılı MN, Karaman A, Karaman İ, Erdoğan D, Çavuşoğlu YH, Aslan MK, Cakmak O. A sewing needle migrating into the liver in a child: case report and review of the literature, *Pediatr Surg Int.* 2007; 23(11):1135–1137.
5. Nishimoto Y, Suita S, Taguchi T, Noguchi S, Ieiri S. Hepatic foreign body-a sewing needle-in a child. *Asian J Surg.* 2003; 26(4):231–233.
6. Le Mandat-Schultz A, Bonnard A, Belarbi N, Aigrain Y, De Lagausie P. Intrahepatic foreign body laparoscopic extraction. *Surg Endosc.* 2003; 17(11):1849.